IJMAHS

RESEARCH ARTICLE

INCIDENCE OF ANOMALOUS PECTORODORSAL MUSCLE IN CADAVERS

Rashmi Patil[1] , Praveen Iyer[2]

[1,2]Department of Anatomy, Seth G S Medical College & KEM Hospital,

Parel, Mumbai – 400012 India

Correspondence to: Dr. Rashmi Patil (dr_rashmipatil@rediffmail.com)

ABSTRACT:

A number of accessory muscle slips connected with the pectoralis major muscle or lying in the axillary region have been described under a variety of names. Many of these bundles are grouped together as "axillary arch" muscles, regardless of whether they arise from the pectoral or the latissimus muscle. These bands may not be of any clinical significance at all. But sometimes, they may present as an axillary mass and can exert pressure on the neighbouring neurovascular structures. A prospective study was planned and the 30 cadavers which were routinely dissected by the first year undergraduate students were observed for the existence of such an anomalous mass. In one of the adult male cadavers, it was found extending between the latissimus dorsi muscle and the pectoralis major muscle of the right upper limb. It measured 7 cm. in length and 2 cm. in breadth. It was innervated by the thoracodorsal nerve. The different nomenclatures, embryological basis and possible clinical significance of such an anomaly are discussed further.

Key words: Axillary arch, Pectorodorsal muscle, Latissimus dorsi, Pectoralis major, Thoracodorsal nerve.

INTRODUCTION:

Variation may be considered as a rule rather than an exception in Anatomy. Some of the variations are of considerable clinical significance, e.g. differences in the anastomotic arrangement between the arteries at the base of the brain, while others may not have much significance, e.g. an extra belly to a particular muscle or the marked difference in the arrangement of the superficial veins even on the two sides of the body. Knowledge of anatomical variations has gained more importance due to wide use and reliance on computer imaging in diagnostic medicine. The presence of anatomical variations is often used to explain symptoms. It is not uncommon to find an accessory muscle mass in the axilla. A number of accessory muscle slips connected with the pectoralis major muscle or lying in the axillary region have been described under a variety of names (Hollinshead, 1982). They may pass between the edge of latissimus dorsi, midway in the posterior fold of the axilla, over the front of the axillary vessels and nerves, and the tendon of pectoralis major, coracobrachialis or fascia over the biceps. This muscular arch is usually 7-10 cm in length and 5-15 mm breadth. It occurs in about 7% of the population and may be multiple (Williams et al, 1995). They may form a complete arch which crosses the axilla and may attach into the fascia of the arm, into the flexor muscles of the arm or extend down as "chondroepitrochlearis muscle" as far as the medial epicondyle (Hollinshead, 1982).

Many of these muscle bundles are grouped together as "axillary arch" muscles regardless of whether they arise from the pectoralis major or latissimus dorsi muscle. Other accessory muscle slips that form less definite arches have also been described and named. They may arise from the thoracic fascia or the external oblique aponeurosis,

from ribs or costal cartilages, and insert into the coracoid process. They sometimes arise from the sternum or the coracoid process and insert into the clavicle. The common variety of axillary arch is a fleshy slip of varying dimensions, often divided by a tendinous intersection, which extends from latissimus dorsi, through the axillary fascia, to pectoralis major, or to the short head of biceps brachii, or to the coracoid process of the scapula. Slips arising from digitations serratus anterior anterior on ribs 6 and 7 and joining pectoralis minor or coracobrachialis have also been described as axillary arch muscles (Bergman et al, 2004). Such bands may present as a mass in the axilla and may exert pressure on the neighbouring neurovascular bundle or lymph routes, thus, producing a wide range of symptoms (Turgut et al, 2005).

MATERIALS AND METHODS:

A prospective study was conducted on 30 cadavers in the Department of Anatomy, Seth G S. Medical College, Mumbai. The dissections of right and left axilla of the cadavers were carried out as a part of routine dissection for the first MBBS students. The 60 dissected upper limb were specifically introspected for the presence of the anomalous band – the pectorodorsalis muscle.

RESULTS AND DISCUSSION:

Out of the 60 upper limbs dissected, in one of the right upper limb of an adult male cadaver, it was found that a musculotendinous mass extended from the upper margin of the latissimus dorsi muscle to the pectoralis major muscle. It passed through the axillary fascia. It measured 7 cm in length and 2 cm in breadth. It was innervated by the thoracodorsal nerve (Figure1).

The axillary arch is also known as Langer's axillary arch or axillopectoral muscle (Sachatello, 1977). Such a slip extending from the latissimus dorsi muscle to the pectoralis major muscle has also been termed as '*achselbogen*' or pectorodorsal muscle. These axillary arch muscles were discovered by Ramsay in 1795 and have a frequency of about 7% in dissecting room specimens (Bergman et al, 1988). However this ratio may be variable and is probably related to sample size as well as differences based on genetics (Yuskel M, 1996). Takafuji et al (1991) studied the muscle and its innervation in Japanese adults and found the incidence to be 6.4% of the total bodies and 5.3% of the limbs. Le Double in 1897 found the incidence to be 7.7%, Kasai and Chiba reported the incidence to be 9% for muscular arches and 17% for tendinous axillary arch, Kutiyanawala et al in 1998 described the incidence to be 6% (Merida-Velasco J R et al, 2003). Velasco- Merida J R et al (2003) also reported the findings of four cases out of 2000 axillary dissections made by Serpell and Baum in 1991 and stated that this low incidence may reflect a previous lack of knowledge about this anatomical variation. They also quoted Haagensen who, in 1986, noted that during radical mastectomy the surgeon frequently observes the axillary arch because it is present in about 7.7% of human subjects of European Stock.

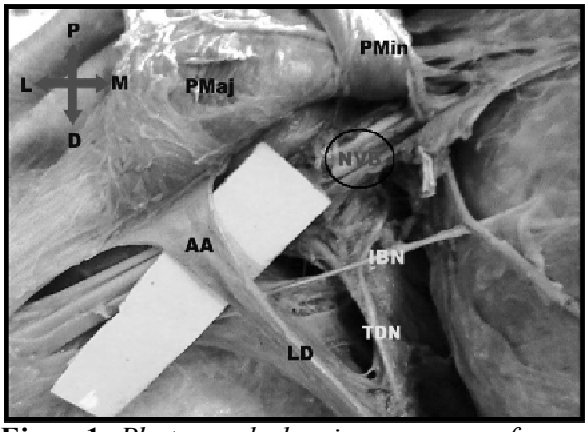

Figure1: *Photograph showing presence of Pectorodorsal muscle (black arrow) in the right axilla of an adult male cadaver.*
Pmin – Pectoralis minor, PMaj – Pectoralis major, NVB- NeuroVascular Bundle, LD- Latissimus Dorsi, IBN- IntercostoBrachial Nerve, TDN- ThoracoDorsal nerve

The innervation of the axillary arch muscles varies. Apparently the innervation of an axillary arch muscle is more frequently from the medial pectoral nerve, but sometimes by the intercostobrachial or by the medial

cutaneous nerve of the arm. Those axillary arch muscles that are closely connected to the latissimus dorsi may be supplied by its nerve, the thoracodorsal (Hollinshead, 1982). In our finding the pectorodorsal muscle was innervated by the thoracodorsal nerve.

The nerve supply of the axillary arch gives an indication of its possible development. It is associated with the development of the muscle supplied by the same nerve. Limb muscles arise in situ from the mesenchyme around the developing bone, the mesenchyme being derived from the somatopleuric layer of the lateral plate mesoderm. Cihak, in 1972, described four fundamental phases in the ontogenesis of muscle pattern. The muscle anomaly described here could have arisen during phases 3 and 4 of ontogenesis of the muscles in the right axilla. During phase 3 some muscle primordia from different layers fuse to form a single muscle. Grim, in 1972, however, stated that some muscle primordia disappear through cell death despite the fact that the cells within them have differentiated to the point of containing myofilaments (Dharap A, 1994). Persistence of some cells between latissimus dorsi and the pectoralis major may account for the muscular slip in the case described. Thus, if the axillary arch muscle is supplied by the medial pectoral nerve then it is derived from the pectoral muscle mass and if it is supplied by the thoracodorsal muscle, it is derived from the muscle mass developing into the latissimus dorsi muscle (Hollinshead, 1982). Since, in our case, the pectorodorsal muscle was supplied by the thoracodorsal nerve, it falls into the latter category.

Such axillary arch muscles have been better reported in apes than in man as quoted by Huntington (Hollinshead, 1982). It may be derived from the panniculus carnosus group of muscles. It might represent a rudimentary phylogenetic remnant in the early human embryonic stage (Takafuji et al, 1991).

The axillary arch needs to be considered in the differential diagnosis of axillary-subclavian venous obstruction as well as in soft tissue axillary masses. It also needs to be considered in cases of hyperabduction syndrome which is characterized by positional venous engorgement and oedema, with relatively minimal neurologic or arterial involvement (Sachatello, 1977). To determine the etiology of a compression syndrome in the cervico-axillary region the physician should evaluate the possible presence of an axillary arch. After physical examination, its presence must be confirmed by Magnetic resonance imaging (Merida-Velasco J R et al, 2003). Clinically, the presence of an anomalous axillary muscle can be suspected by a combination of history of intermittent axillary vein obstruction, loss of the normal axillary concavity, visual fullness in the axilla and a palpable mass (Sachatello, 1977). If an axillary arch is encountered during axillary lymphadenectomy, the lymph nodes posterior and lateral to the arch should be excised. Experience with a number of such cases could be used to consider local therapeutic and staging factors (Petrasek et al, 1997). Clinicians should recognize and excise the axillary arch muscles to expose the axillary artery, vein and lymph nodes in patients of trauma and to perform axillary lymphadenectomy or axillary bypass (Miguel et al, 2001).

ACKNOWLEDGEMENT:

We would like to thank Dr. Pritha Bhuiyan, Professor & Head and Dr. Lakshmi Rajgopal, Additional Professor from the Department of Anatomy, Seth G S Medical College & KEM Hospital, Mumbai, for providing us the opportunity to present this paper.

REFERENCES:

1. Bergman RA, Thompson SA, Afifi AK, Saadeh FA. Compendium of Human Anatomic Variations, Text, Atlas and World Literature, In: Nervous system, Urban & Schwarzenburg, Baltimore & Munich. 1988. Pg. 10.
2. Bergman RA, Afifi AK, Ryosuke Miyauchi. Virtual Hospital Illustrated Encyclopedia of Human Anatomic Variation: Opus I: Muscular System: Alphabetical Listing of Muscles:A. 2004. Available from : http://www.anatomyatlases.org/AnatomicVariants/MuscularSystem/Text/A/47Axillary.shtml (Accessed on 03.07.2015).
3. Dharap A. An unusually medial axillary arch muscle. Journal of Anatomy 1994.184: 639-641.
4. Hollinshead WH. Anatomy for Surgeons, Vol. 3. Back and Limbs, Third edition, Harper and Row, New York. 1982. Pp. 280-281.
5. Merida-Velasco J R, Rodriguez Vazquez J F, Merida-Velasco J A, Sobrado Perez J, Jimenez Collado J. Axillary arch: Potential Cause of Neurovascular Compression Syndrome. Clinical Anatomy 2003.16: 514-519.
6. Miguel M, Llusa M, Ortiz JC, Porta N, Lorente M, Gotzens V. The axillopectoral muscle (of Langer): report of three cases. Surg Radiol Anat. 2001.23(5): 341-343(ABSTRACT) Available from :http://www.ncbi.nlm.nih.gov/entrez/query.fcgi?cmd=Retrieve&db=pubmed&dopt=Abstract&list_uids=11824135&query_hl=3
7. Petrasek A J, Semple J L, McCready D R. The surgical and oncologic significance of the axillary arch during axillary lymphadenectomy. Canadian Journal of Surgery. 1997.40(1): 44-47 (ABSTRACT) Available from: http://www.ncbi.nlm.nih.gov/entrez/query.fcgi?db=pubmed&cmd=Retrieve&dopt=Abstract&list_uids=9030083&query_hl=6&itool=pubmed_docsum(Accessed on 03.07.15).
8. Sachatello C R. The axillopectoral muscle (Langer's axillary arch): A cause of axillary vein obstruction. Surgery. 1977.81(5): 610-612.
9. Takafuji T, Igarashi J, Kanbayashi T, Yokoyama T, Moriya A, Azuma S, Sato Y. The muscular arch of the axilla and its nerve supply in Japanese adults. Kaibogaku Zasshi. 1991.66(6):511-23.(ABSTRACT).Available: http://www.ncbi.nlm.nih.gov/entrez/query.fcgi?cmd=Retrieve&db=pubmed&dopt=Abstract&list_uids=1816715&query_hl=3
10. Turgut HB, Peker T, Gulekon N, Anil A, Karakose M. Axillopectoral muscle (Langer's muscle). Clinical Anatomy 2005.18 (3): 220-223. (ABSTRACT). Available from the: http://www3.interscience.wiley.com/cgi-bin/abstract/ 110430203/ABSTRACT (Accessed on 03.07.15) DOI: 10.1002/ca.20077.
11. Williams P L, Bannister LH, Berry MM, Collins P, Dyson M, Dussek JE, Fergusson MWJ. Gray's Anatomy-The Anatomical Basis of Medicine and Surgery In:Muscle 38th edition, Churchill Livingstone, Edinburgh, 1995. Pg. 837.
12. Yuksel M, Yuksel E, Surucu S. An axillary arch. Clinical Anatomy 1996.9 (4): 252-254.

Cite this article as: **Rashmi Patil** , **Praveen Iyer,** Incidence of Anomalous Pectorodorsal Muscle in Cadavers, *Int* J Medicine and Allied Health Sciences, 2015; 6: 633-636